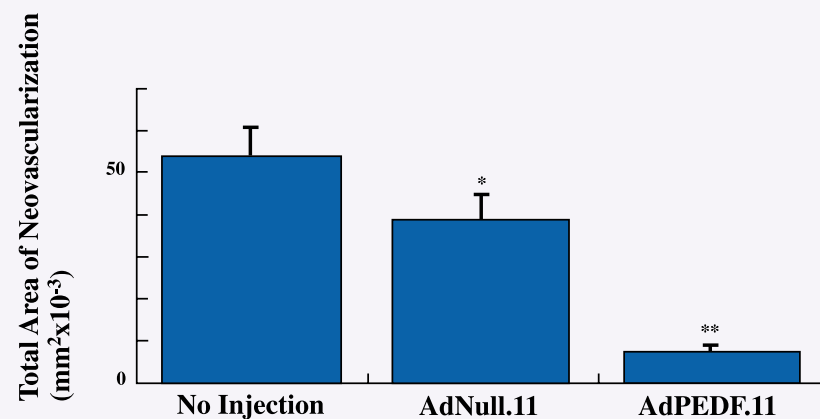


SAFETY OF INTRAVITREAL DELIVERY OF ADENOVIRUS IN CYNOMOLGUS MONKEYS

HS Rasmussen¹, WH Bee², MC Wills², RJ Munger², RJ Durham¹, EB Smidt¹, LL Wei¹

¹GenVec, Inc., Gaithersburg, MD; ²Sierra Biomedical, Sparks, NV

1) Background: Aberrant choroidal (CNV) or retinal neovascularization (RNV) is a key pathogenic factor for the development of a variety of ocular diseases, including neovascular age-related macular degeneration and proliferative diabetic retinopathy. Pigment Epithelium-Derived Factor (PEDF) has potent antiangiogenic and neurotrophic properties and appears to be the key natural regulator of vascularity in the eye. AdPEDF is a second-generation (E1-, E4-, and partially E3-deleted) adenovector, carrying the transgene encoding for PEDF. AdPEDF, administered intravitreally or subretinally, has demonstrated substantial activity in prevention of ocular neovascularization in three different murine models (VEGF transgenic model, ROP model and CNV laser model) as exemplified in the figure below.



Inhibition of retinal neovascularization in a VEGF transgenic mouse model after a single intravitreal injection of AdPEDF (Mori K *et al. J Cell Physiol*, 2001. 188:253-263).

2) Purpose: The purpose of the studies was to characterize the safety and toxicity profile of AdPEDF, to identify the dose-limiting toxicities and establish a no adverse effect dose level.

3) Methods: Single intravitreal injections of AdPEDF at doses of 1 x 10⁸, 1 x 10⁹, 1 x 10¹⁰ and 5 x 10¹⁰ pu and repeat (days 0 and 22) injections of 1 x 10⁹ pu were performed in one eye of 22 primates (cynomolgus monkeys). No treatment, or a comparable volume of saline or final formulation buffer (FFB) (50 µl) was delivered to the contralateral eye. Safety was assessed by direct and indirect ophthalmologic examinations (baseline and days 3, 8, 15 and 22), electroretinography (ERG) (baseline and day 22)*, tonometry (baseline and day 22) and, after sacrifice of the animals, histopathology of the eyes.

In the repeat dose animals, ophthalmologic examinations were performed at baseline and on days 3, 8, 15, 22, 29, 36, 43, 50, 57, 64, 71, and 85 with tonometry and ERGs at baseline and on day 78.

*Note some animals did not have ERGs at baseline.

4) Results:

Dose	1x10 ⁸ pu (GV ₁₁)	1x10 ⁹ pu		5x10 ¹⁰ pu	
		^(a) GV ₁₀	^(b) GV ₁₁	^(a) GV ₁₀	^(b) GV ₁₁
Ophthalmologic examination					
^(c) Inflammation	0	+	+	+++	+++
Electroretinography (ERG)					
Normal	X	X	X		
Abnormal				X ^(d)	X ^(e)
Histopathology					
^(c) Inflammation	0	+	+	+/+	+/+/+

Table keys:

^(a) GV₁₀ = 1st generation vector (E1-, E3-deleted)

^(b) GV₁₁ = 2nd generation vector (E1-, E3- and E4-deleted)

^(c) Grading of Inflammation

0 = None + = Minimal ++ = Mild +++ = Moderate ++++ = Severe

^(d) All monkeys showed decreased amplitudes

^(e) 1 of 4 was normal; 1 of 4 showed abolished scotopic blue and red responses with white response showing reduced amplitudes; 1 of 4 showed abolished ERG response for all light stimuli; 1 of 4 showed decreased amplitude with prolonged latency for all light stimuli.

Dose Groups:

Group I: Control groups (no treatment, saline or FFB): 22 eyes

Group II: AdPEDF_{GV11} 1 x 10⁸ pu: 2 eyes

Group III: AdPEDF 1 x 10⁹ pu: 6 eyes
(3 eyes with GV₁₀, 3 eyes with GV₁₁)

Group IV: AdPEDF_{GV11} repeat dose 1 x 10⁹ pu: 3 eyes

Group V: AdPEDF_{GV11} 1 x 10¹⁰ pu: 3 eyes

Group VI: AdPEDF 5 x 10¹⁰ pu: 4 eyes
(2 eyes with GV₁₀, 2 with GV₁₁)

Group VII: AdPEDF_{GV11} 5 x 10¹⁰ pu with systemic steroids: 2 eyes

Group VIII: AdPEDF_{GV11} 5 x 10¹⁰ pu without systemic steroids: 2 eyes

5) Conclusions:

- Intravitreal administration of AdPEDF was well tolerated at potential therapeutic doses.
- AdPEDF caused a dose-related inflammatory response, ranging from:
 - None (1 x 10⁸ pu)
 - Minimal and reversible (1 x 10⁹ pu)
 - Moderate (1 x 10¹⁰ pu)
 - Severe (5 x 10¹⁰ pu)
- The no adverse effect dose was 1 x 10⁸ pu.
- Dose of 1 x 10⁹ pu caused minimal inflammation, which was fully reversible.
- Repeat dosing (1 x 10⁹ pu) is feasible without an increase in toxicity.
- The 2nd generation vector (E1-, E3- and E4-deleted) caused less inflammation than a 1st generation vector (E1- and E3-deleted).
- The intra-ocular inflammatory responses were non-suppurative and mononuclear, indicative of a cellular immune response.
- No systemic toxicities were observed at any dose level.
- Systemic administration of steroids caused some reduction in inflammation, although substantial inflammation remained at the top dose.
- Entry into Phase I clinical trials is justified.